

Vol. 11 No. 1-4 (2020)

DOI: [10.59987/ads/2020.1-4.28-32](https://doi.org/10.59987/ads/2020.1-4.28-32)

Ultrashort implant in the upper jaw, an alternative therapeutic procedure after the failure of the sinus lift: a case report

G. Botticelli, E. Calabria, M. Severino, G. Foffo, P. Petrelli, M. Galli, E. Calabria, A. Giudice, R. Gatto, G. Falisi

Keywords: ultrashort implants, sinus lift, bone regeneration failure

Abstract

The rehabilitation of the posterior sites of the maxilla with dental implants is a therapeutic procedure often influenced by the atrophy of the maxillary bone, caused by either the loss of dental elements or by the maxillary sinus pneumatization. Bone loss in the upper maxillae which prevents the placement of implant fixture, may be fixed with surgical bone regenerations techniques, such as the sinus lift, or with the placement of zygomatic and/or pterygoid implants. Although the proved effectiveness of these invasive therapeutic approaches, the biological and economic costs may be high. Also, the failure of these procedure, may further prevent the possibility of a second implant rehabilitation. In this scenario, the use of the short and ultra-short implants may be considered a valid minimally invasive alternative for the rehabilitation of the atrophic edentulous crests. Here, we describe a case of a female patient presenting with atrophic posterior maxilla which was rehabilitated with an implant of 3 millimeters in length after the failure of a previous surgical maxillary sinus lift through lateral window approach and with a total follow-up of 36 months.

Ultrashort implant in the upper jaw, an alternative therapeutic procedure after the failure of the sinus lift: a case report

Gianluca Botticelli¹

Ennio Calabria^{2*}

Marco Severino¹

Giordano Foffo³

Pierpaolo Petrelli⁴

Massimo Galli⁵

Calabria E⁶

Giudice A⁷

Gatto R¹

Giovanni Falisi¹

¹ Department of Life Health and Environmental Sciences, University of L'Aquila, 67100, L'Aquila, Italy

² Department of Neuroscience, Reproductive Sciences and Dentistry, University of Naples Federico II, Naples, Italy

³ Private practitioner, L'Aquila, Italy

⁴ Department of Innovative Technologies in Medicine & Dentistry, University of Chieti—Pescara 'Gabriele d'Annunzio', 66100 Chieti, Italy

⁵ Department of Oral and Maxillofacial Sciences, University of Rome La Sapienza, Rome, Italy

⁶ Private practitioner, Lamezia Terme, Catanzaro, Italy

⁷ Department of Health Sciences, School of Dentistry, University of Catanzaro "Magna Grecia", Catanzaro Italy.

*Corresponding author:

Elena Calabria, DDS, PhD

calabrielena92@gmail.com

Abstract

The rehabilitation of the posterior sites of the maxilla with dental implants is a therapeutic procedure often influenced by the atrophy of the maxillary bone, caused by either the loss of dental elements or by the maxillary sinus pneumatization.

Bone loss in the upper maxillae which prevents the placement of implant fixture, may be fixed with surgical bone regeneration techniques, such as the sinus lift, or with the placement of zygomatic and/or pterygoid implants. Although the proved effectiveness of these invasive therapeutic approaches, the biological and economic costs may be high. Also, the failure of these procedure, may further prevent the possibility of a second implant rehabilitation. In this scenario, the use of the short and ultra-short implants may be considered a valid minimally invasive alternative for the rehabilitation of the atrophic edentulous crests. Here, we describe a case of

a female patient presenting with atrophic posterior maxilla which was rehabilitated with an implant of 3 millimeters in length after the failure of a previous surgical maxillary sinus lift through lateral window approach and with a total follow-up of 36 months.

Key words: ultrashort implants, sinus lift, bone regeneration failure

Introduction

Implant-supported fixed prostheses represent a highly reliable therapeutic option and one of the most predictable dental procedures for treating partial posterior jaw edentulisms¹⁻³.

The rehabilitation of posterior jaws may be clinically challenging, especially when the residual bone volume does not allow the proper insertion of implants with a standard length of at least ten mm⁴.

In these situations, the placement of implants may present an anatomical issue due to the potential damage to noble anatomical structures such as the inferior alveolar nerve or the maxillary sinus⁵.

In addition, the implant rehabilitation of the posterior regions of the upper maxilla may be even more complicated by the volume reduction of the available bone due to the loss of dental elements and the maxillary sinus pneumatization⁶⁻¹⁰.

When the volume of the bone is inadequate for the placement of standard implants, bone augmentation procedures are generally performed to provide the correct bone volume quantity¹¹.

According to Misch, to perform an implant rehabilitation of the posterior maxilla in case of a width of bone < 5mm - category SA4, it is recommended to perform a maxillary sinus augmentation procedure through a lateral window approach with a delayed positioning of the implant fixture¹²⁻¹³. Complications of this procedure are perforation of the Schneiderian membrane (25.7%), rhino-sinusitis (4.2%-8.4%), exposure of the bone graft (3.1%), and loss of the graft (1.6%)¹⁴⁻¹⁹.

Another approach in the case of maxillary atrophy is using zygomatic implants. However, studies have demonstrated a higher number of complications with zygomatic surgery compared to traditional sinus lift and implant positioning procedures²⁰⁻²¹.

In recent years, the use of short (5-10 mm) and ultrashort implants (< 5 mm in length) has been suggested as an alternative therapy to such surgical options for prosthetic restoration in resorbed jawbones^{4,5,22}. Patients treated with short and ultrashort implants may benefit from a rehabilitation based on fewer surgical procedures, with

less invasiveness and minor postoperative discomfort or complication²³.

We report the case of a female patient presenting with severe maxillary atrophy, which was rehabilitated by inserting an ultra-short implant of 3 millimeters associated with the technique of a minimal invasive crestal sinus lift after the failure of a previous maxillary sinus lift.^{28,29,30}

Case report

A female patient, 47 years old, a smoker with an unremarkable medical history, was referred to the dental clinic of the University of L'Aquila (Italy) to rehabilitate the partial posterior edentulism in the upper left maxilla. She reported that two years before, she had the first up-

per left molar extracted (tooth 2.6- figure 1) because of a vertical fracture following the endodontic treatment.

The patient reported that about four months following the tooth extraction, she underwent a maxillary sinus augmentation through the lateral window approach, with the insertion of biomaterial grafting. However, she further reported having developed acute sinusitis of the left maxillary sinus after two weeks as complications of the surgical procedure, requiring a second surgery to remove the grafting material. After 18 months, the clinical situation was an atrophy degree of < 5mm - category SA4 (Figure 2), so we first proposed the second procedure of sinus floor elevation.

However, the patient was looking for an alternative, less invasive solution.

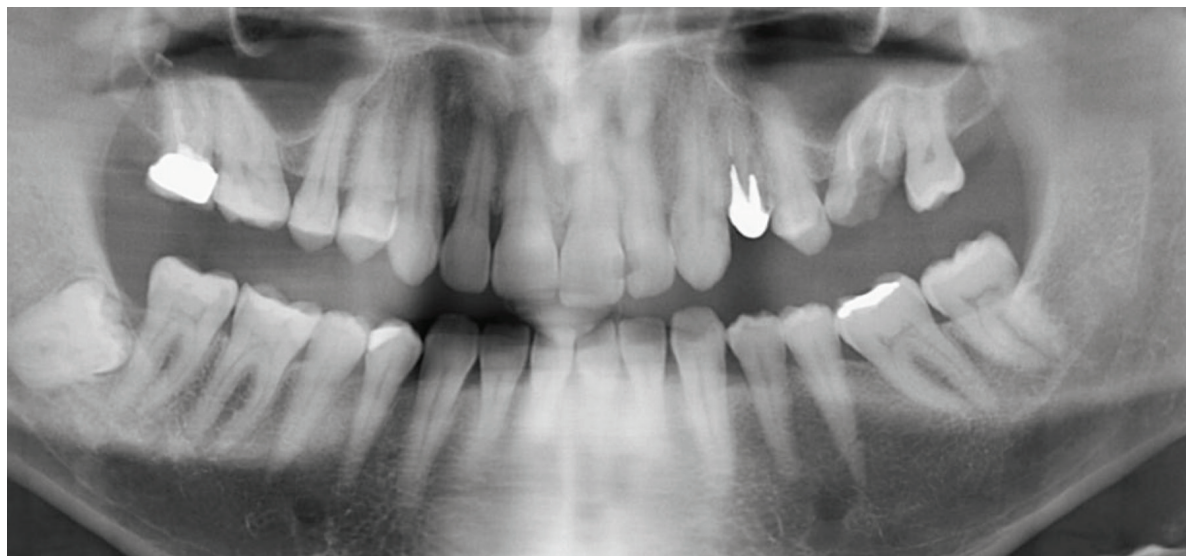


Figure 1. OPG of the patient referring to the period when the first upper left molar was still present.

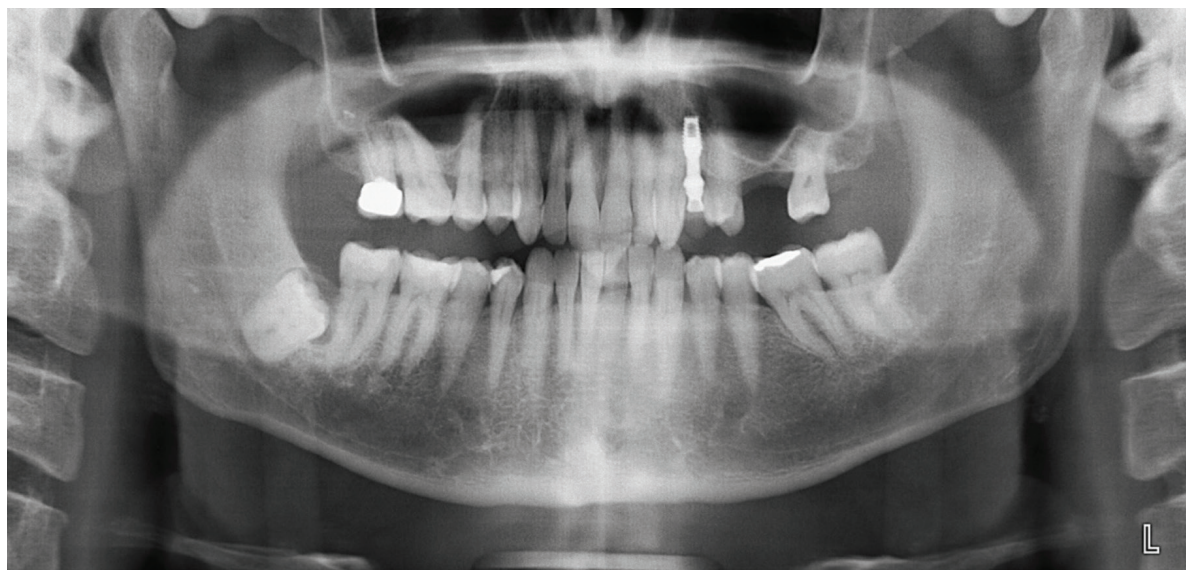


Figure 2. OPG of the patient which highlights the absence of the dental element 2.6 and the severe maxillary atrophy.

Since the residual maxillary bone height measured 3 mm, we suggested positioning an ultra-short implant in association with a minimal invasive crestal sinus lift. Then, using the same implant as the residual bone compaction tool along with its insertion, without performing further bone increase.

An ultra-short implant of 3 mm and 5.1 mm in diameter was placed. The implant was made of Titanium of grade 4, with a sandblasted and etched surface, and characterized by a conometric connection with 4° degree, with a complete tubular section, hollow inside (IM Maco, Maco International). This fixture is characterized by a flat, self-taping apical portion with a plateau. The coronal platform is inclined with a trapezoidal section to increase the bone contact surface. The implant-abutment presents a transmucosal length of 3 mm.

Antibiotic prophylaxis was scheduled based upon administering two gr/day of amoxicillin starting 1 hour before the surgical intervention and continuing for the next three days every 12 hours²⁴. Before the surgery, oral disinfection was performed with chlorhexidine (0.2% solution for one minute). Local anesthesia (OPTOCALN®, 20 mg/m with adrenalin 1:80,000. Molteni Dental— Italy) was administered on both vestibular and palatal mucosa. First, a total-thickness mucoperiosteal flap was raised to reveal the underlying alveolar bone. The protocol preparation phase of the implant site consisted of a first perforation of the bone using a lanceolate burr, maintaining intact the cortex of the sinus floor, and proceeding sequentially by using the preparation burs to obtain a slightly less deep implant site. Once the planned diameter of the site

was prepared (with a reduced depth to that one needed), a pellet of equine collagen (Congress - Smith&Nephew) was placed inside the prepared surgical site. Afterward, the implant was placed in the preparation site to determine a greenstick fracture of the maxillary sinus floor.

The implant surgical site was prepared with a diameter equal to that of the ultrashort implant; thus, the implant placement was performed by giving a simple and controlled push to the fixture. The surgical site was sutured with VICRYL TM - Ethicon (caliber: 4/0, color: purple, shape: cylindrical, needle length: 17.4 mm, gauge: 21). The sutures were removed seven days later. The patient was provided with postoperative instructions, including antibiotic therapy as indicated, the use of non-steroidal anti-inflammatory drugs as needed, and the intake of a liquid diet for three days. In addition, the patient was recommended to use chlorhexidine spray 0.2% for four days, cleansing with 10% hydrogen peroxide using a sterile hydrophilic gauze to be passed over the sutures. After about four months after the first operation, the second surgical procedure was performed to expose the head of the implant and remove the healing screw. A Titanium abutment of grade 5 was placed, and a provisional prosthesis was made in acrylic resin and then applied. After two months, the final crown in layered zirconium was cemented (Figure 3a).

The patient attended a clinical follow-up twice a year as part of her routine oral hygiene program. The radiographic follow-up at 12 and 36 months from the masticatory load highlights a good osteointegration of the fixture (Figures 3b and 3c).

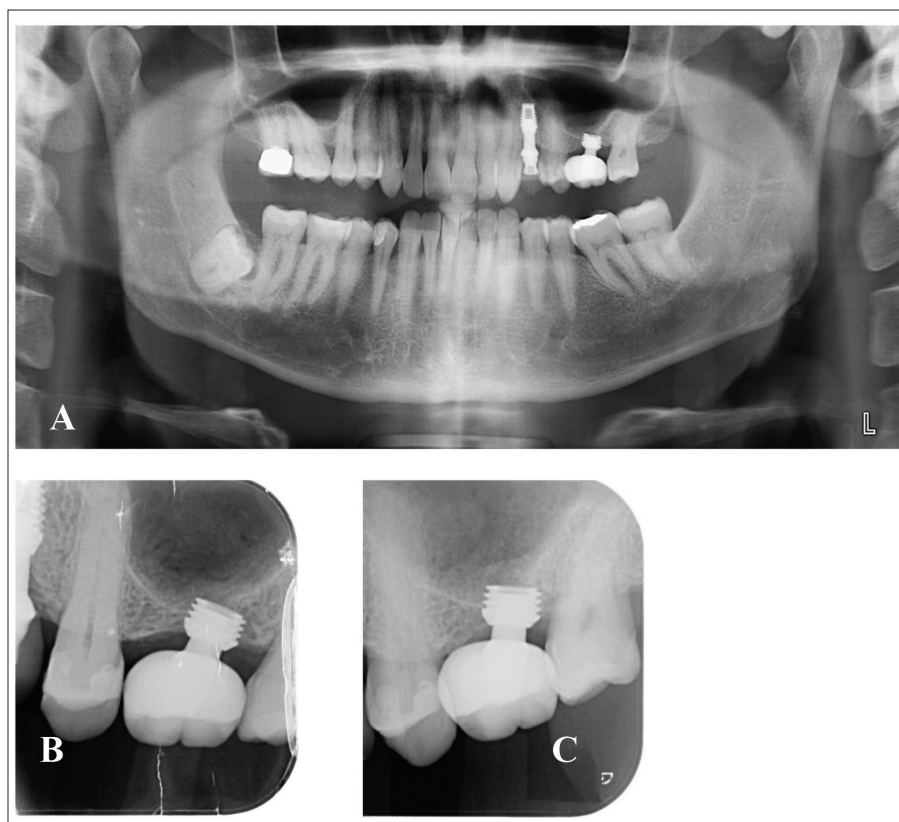


Figure 3. A. Orthopantomogram showing the definitive crown visible in the second quadrant B. periapical x-ray one year after implant loading. C. periapical x-ray examination three years after implant loading.

Discussion

Even with modern technology for guided bone regeneration, the insertion of implants within a resorbed bone may not be predictable⁴.

The surgical procedures aiming at obtaining the bone augmentation, or the use of a zygomatic implant, are generally invasive, expensive, often requiring a higher number of surgical procedures, associated with post-operation complications, and require more extended periods (up to 1 year) for the prosthetic load⁴.

The predictability of short and ultra-short implants in implant-supported prosthetic rehabilitations has been debated in the last years. Also, the definition of short implant presents disagreements; some researchers define them as fixtures ranging from 7 to 10 mm, whereas others consider them to be "short" implants with a length < 8 < 7 or of 6 mm. Finally, researchers agree on considering ultra-short implants length of 4 millimeters or less²³.

Das Neves et al. reported that short implants are advisable as an alternative approach to advanced surgical procedures for bone augmentation due to lower morbidity, reduced operation time, and lower costs for the patient²⁵.

Another study conducted in 2014 comparing the long-term outcomes between short and long implants (with sinus lift) reports no evident differences in the survival of the implants and prosthetic failures²⁶. A recent retrospective study evaluating the implant success rate of 50 ultra-short dental implants after a follow-up of 8-10 years reported a success rate of 94% and that the ultra-short implants proved to be a reliable solution for prosthetic restoration in patients with severe alveolar bone atrophy²³.

Another study reported that in patients who underwent the rehabilitation of the complete arch using ultrashort implants, the critical rehabilitation issues occur in the first week and after four months following implant placement together with the prosthetic load²².

The presented case showed a patient successfully treated with an ultra-short implant of 3 millimeters after the failure and complication of a sinus lift, with a total follow-up of 36 months, confirming the reliability of the ultra-short implant as a valid and effective therapeutic option for severe atrophy bone. If confirmed by in vivo studies, this option may be chosen in case of the general poor health of the patients or contraindications to the major surgical procedures, and those patients willing to a minimally invasive approach²⁷.

Using an ultra-short implant of 3 millimeters was a practical approach in rehabilitating a posterior edentulism in severe maxillary bone atrophy after the failure of a sinus lift. However, further research involving a large sample of patients with a longer follow-up must confirm the results.

Acknowledgements

We wish to thank Doctor Ennio Calabria for his collaboration in the execution of the surgical procedure and prosthesis rehabilitation of the case presented.

Conflict of Interest

None.

References

1. Tomasi C, Wennström JL, Berglundh T. Longevity of teeth and implants: a systematic review. *J Oral Rehabil* 2008; 35 (Suppl 1):23–32.
2. Jung RE, Pjetursson BE, Glauser R, Zembic A, Zwahlen M, Lang NP. A systematic review of the 5-year survival and complication rates of implant-supported single crowns. *Clin Oral Implants Res*. 2008;19(2):119-130.
3. Misch CE, Perel ML, Wang HL, et al. Implant success, survival, and failure: The International Congress of Oral Implantologists (ICOI) Pisa Consensus Conference. *Implant Dent* 2008; 17(1):5–15.
4. Bernardi S, Gatto R, Severino M, et al. Short Versus Longer Implants in Mandibular Alveolar Ridge Augmented Using Osteogenic Distraction: One-Year Follow-up of a Randomized Split-Mouth Trial. *J Oral Implantol*. 2018; 44(3):184-191.
5. Falisi, G., Bernardi, S., Rastelli, C., et al. "All on short" prosthetic-implant supported rehabilitations. *ORAL and Implantology*, 2007; 10 (4): 477-487
6. Atwood DA. Reduction of residual ridges: a major oral disease entity. *J Prosthet Dent*. 1971; 26 (3):266-279.
7. Atwood DA, Coy WA. Clinical, cephalometric and densitometric study of reduction of residual ridges. *J Prosthet Dent*. 1971; 26(3) :280-295.
8. Tallgren A. The continuing reduction of the residual alveolar ridges in complete denture wearers. A mixed longitudinal study covering 25 years. *J Prosthet Dent*. 1972; 27 (2):120-132.
9. Berg H, Carlsson GE, Helkimo M. Changes in shape of posterior parts of upper jaws after extraction of teeth and prosthetic treatment. *J Prosthet Dent*. 1975; 34(3) :262-268.
10. Chanavaz M. Maxillary sinus: Anatomy, physiology, surgery, and bone grafting related to implantology: Eleven years of surgical experience, *J Oral Implantol* 1990; 16(3):199–209.
11. Scarano A, Bernardi S, Rastelli C, Mortellaro C, Vittorini P, Falisi, G. Soft tissue augmentation by means of silicon expanders prior to bone volume increase: A case series. *J Biol Regul Homeost Agents* 2019;33(6 Suppl. 2):77-84. DENTAL SUPPLEMENT
12. Misch CE. Treatment plans for implant dentistry. *Dent Today*. 1993; 12(12): 56-61.
13. Misch CE. Maxillary posterior treatment plans for implant dentistry. *Implantodontie*. 1995; 19(4):7-24.
14. Adell R, Eriksson B, Lekholm U. A long-term follow-up study of osseointegrated implants in the treatment of totally edentulous jaws. *Int J Oral Maxillofac Implants* 1990 5(4): 347–359.
15. Tatum H. Maxillary and sinus implant reconstruction, *Dent Clin North Am* 1986; 30(2) :207–229.
16. Hall HD. Bone graft of the maxillary sinus floor for Branemark implants, *Oral Maxillofac Surg Clin North Am* 1991; 3(4):869–875.
17. Raghoobar GM, Onclin P, Boven GC, Vissink A, Meijer HJA. Long-term effectiveness of maxillary sinus floor augmentation: A systematic review and meta-analysis. *J Clin Periodontol*. 2019;46 (Suppl 21):307-318.
18. Moreno Vazquez JC, Gonzalez de Rivera AS, Gil HS, Mifsut RS. Complication rate in 200 consecutive sinus lift procedures: guidelines for prevention and treatment. *J Oral Maxillofac Surg*. 2014;72(5):892-901.
19. Kayabasoglu G, Nacar A, Altundag A, Cayonu M, Muhtarogullari M, Cingi C. A retrospective analysis of the relationship between rhinosinusitis and sinus lift dental implantation. *Head Face Med*. 2014;10:53.
20. Balaji SM, Balaji P. Comparative evaluation of direct sinus lift with bone graft and zygoma implant for atrophic maxilla. *Indian J Dent Res*. 2020; 31(3):389-395.
21. Pieri F, Caselli E, Forlivesi C, Corinaldesi G. Rehabilitation of the Atrophic Posterior Maxilla Using Splinted Short Implants or Sinus Augmentation with Standard-Length Implants: A Retrospective Cohort Study. *Int J Oral Maxillofac Implants*. 2016;31(5):1179-88.

22. Falisi G, Di Paolo C, Rastelli C, et al. Ultrashort Implants, Alternative Prosthetic Rehabilitation in Mandibular Atrophies in Fragile Subjects: A Retrospective Study. *Healthcare (Basel)*. 2021;9(2):175.
23. Malchiodi L, Ricciardi G, Salandini A, Caricasulo R, Cucchi A, Ghensi P. Influence of crown-implant ratio on implant success rate of ultra-short dental implants: results of a 8- to 10-year retrospective study. *Clin Oral Investig*. 2020;24(9):3213-3222.
24. Botticelli G, Severino M, Ferrazzano GF, Vittorini Velasquez P, Franceschini C, Di Paolo C, Gatto R, Falisi G. Excision of Lower Lip Mucocele Using Injection of Hydrocolloid Dental Impression Material in a Pediatric Patient: A Case Report. *Applied Sciences*. 2021; 11(13):5819.
25. das Neves FD, Fones D, Bernardes SR, do Prado CJ, Neto AJ. Short implants--an analysis of longitudinal studies. *Int J Oral Maxillofac Implants*. 2006; 21(1):86-93.
26. Perelli M, Abundo R, Corrente G, Saccone C. Short (5 and 7 mm long) porous implants in the posterior atrophic maxilla: a 5-year report of a prospective single-cohort study. *Eur J Oral Implantol*. 2012;5(3):265-272.
27. Calabria Ennio. Short Implant di Ultima Generazione, Nuove Prospettive. Edizione Martina 2021
28. Intercepting of Class III Malocclusion with a Novel Mechanism Built on the Orthopaedic Appliance: A Case Report- PMID: 35740723
29. Impact of molar teeth distalization with clear aligners on occlusal vertical dimension: a retrospective study. Caruso S, Nota A, Ehsani S, Maddalone E, Ojima K, Tecco S. *BMC Oral Health*. 2019 Aug 13;19(1):182.
30. Temporomandibular Joint Anatomy Assessed by CBCT Images. Caruso S, Storti E, Nota A, Ehsani S, Gatto R. *Biomed Res Int*. 2017;2017:2916953. doi: 10.1155/2017/2916953. Epub 2017 Feb 2. PMID: 28261607